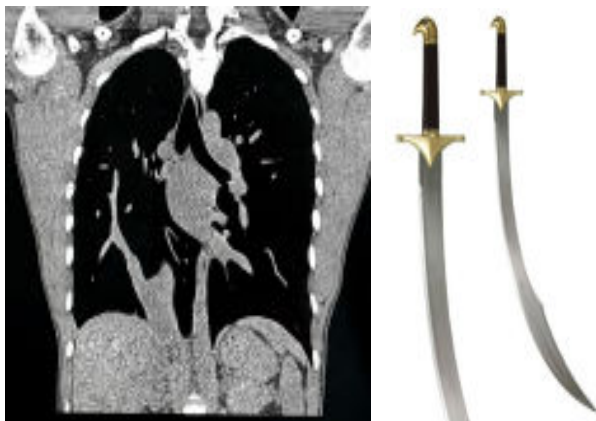

Radiological Signs



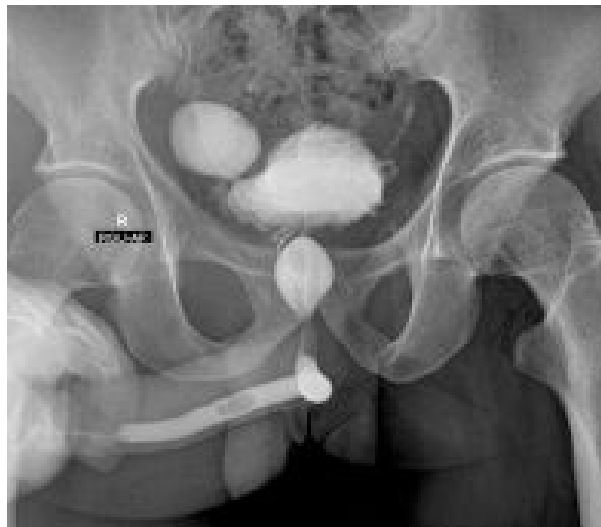Dr Yasna Kibria

Phase B Resident, BSMMU

Awarded First Prize in RadConBD 2022

Schimitar Sign

Anomalous pulmonary vein that drains any or all of the lobes of right lung. So called scimitar vein curves outwards along the right heart border and usually empties into the inferior vena cava.



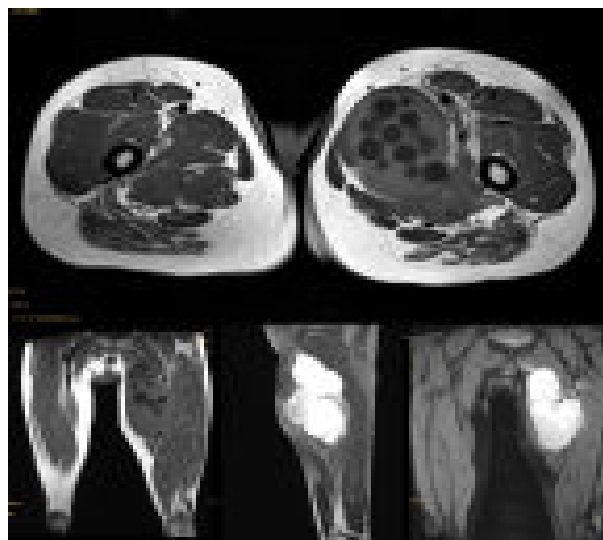
Dr Salma Khatun

Medical Officer

Shaheed Suhrawardy Medical College Hospital, Dhaka

Awarded third prize in RadConBD 2022

RGU showing UB neck stenosis resulting ballooning of prostatic urethra, UB diverticulum & Grade-I VUR (left).



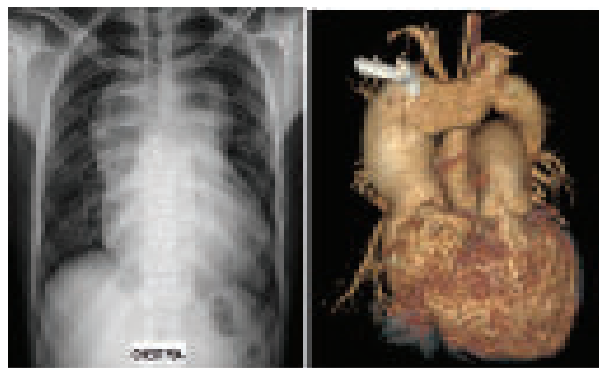
Dr Nusrat Tamanna

Specialist (Radiology & Imaging)

Evercare Hospital, Dhaka

Awarded second prize in RadConBD 2022

An unusual case of **Intramuscular Hydatidosis** showing a large cystic lesion within the adductor muscles of left thigh having multiple daughter cysts.



Dr Nusrat Ghafoor

Associate Professor & Consultant

Radiology & Imaging

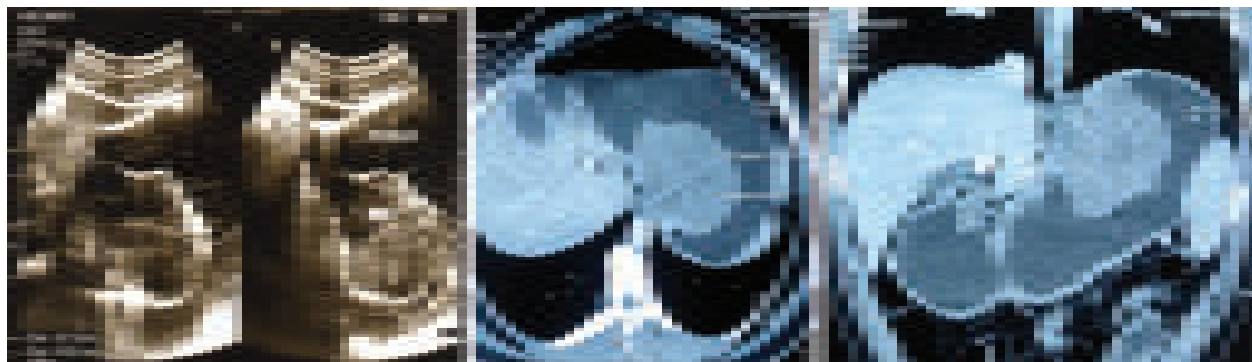
Ibrahim Cardiac Hospital & Research Institute

Dhaka, Bangladesh

Awarded fourth prize in RadConBD 2022

Snowman Sign

VR of Cardiac CT confirms Supracardiac type TAPVC (Total Anomalous Pulmonary Venous Drainage). Chest X-ray shows a para-tracheal shadow on the right is prominent SVC and on the left is the vertical vein.

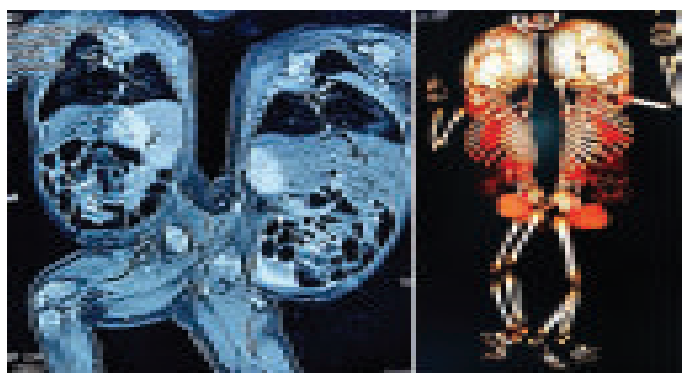

Dr Fahmida Yeshmine

Associate Professor, Dept of Radiology & Imaging, BIRDEM General Hospital, Dhaka
 Awarded fifth prize in RadConBD 2022

GIST

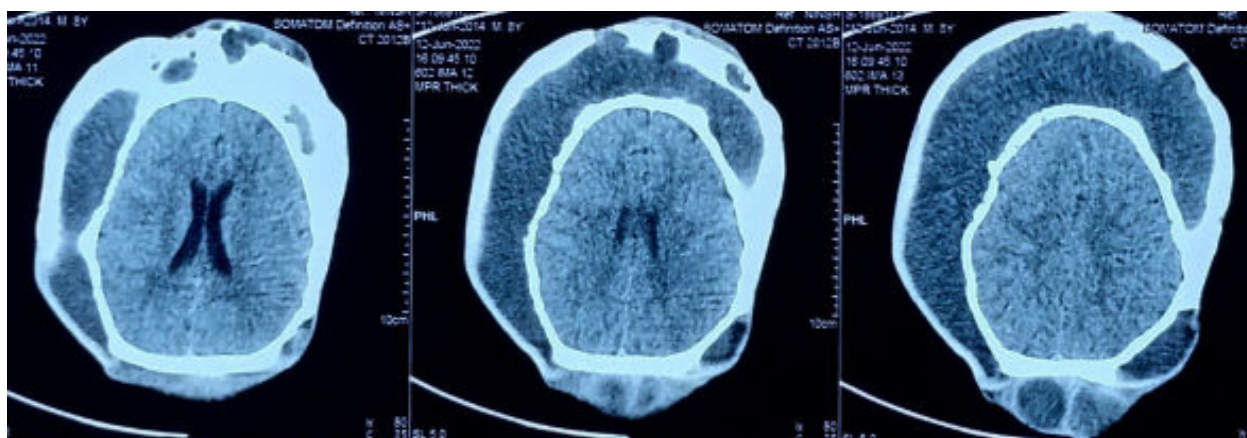
USG - Soft tissue mass in stomach. **CECT** - Soft tissue density lesion in gastroesophageal junction with intraluminal extension.



Dr Shohaila Sharmin Ani
 Phase- B Resident
 BSMMU

Pygopagus

Pygopagus twins are joined dorsally & facing away from each other sharing the sacro-coccygeal & perianal region.

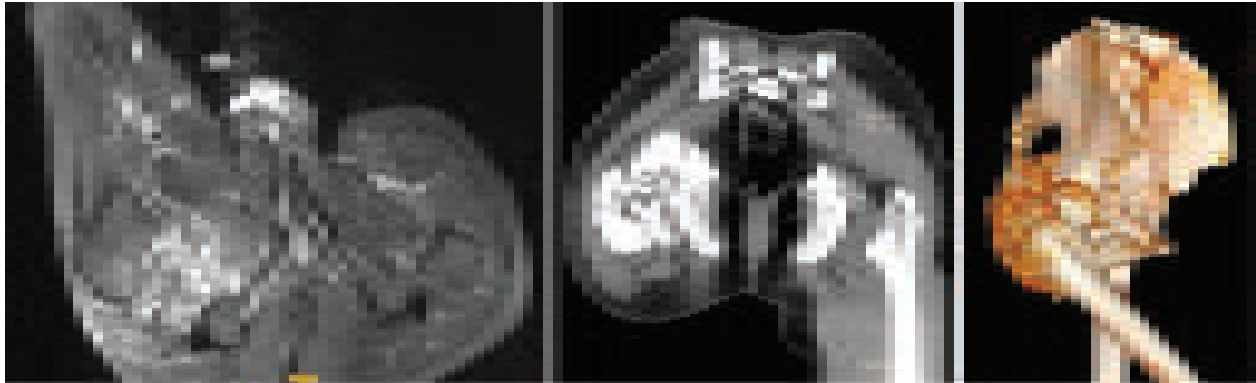


Professor Mst. Nazmun Nahar

National Institute of Neurosciences, Agargaon, Dhaka

Double Skull Sign

NECT of head demonstrates a huge calcified hematoma superficial to the skull and under galea aponeurotica causing a double skull appearance following minor trauma 4 years back.



Dr Mahbuba Azim Moonmoon

Specialist, (Radiology & Imaging), Evercare Hospital, Dhaka

Post traumatic Myositis Ossificans- Sheets of calcifications in the gluteus maximus, gluteus medius, gluteus minimus and obturator internus muscles on right side on a post traumatic male patient.

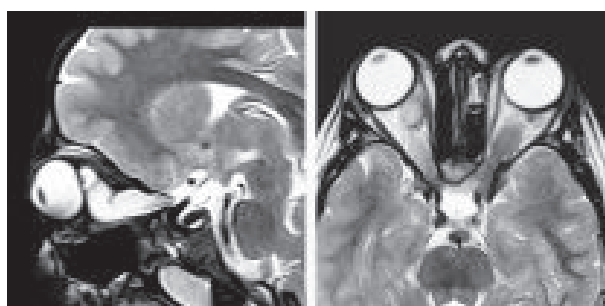


Dr Md Anisur Rahman Khan

Associate Professor, Department of Radiology & Imaging, Colonel Maleque Medical College, Manikganj

Coup-contrecoup

Injury of Brain in NECT Scan of a traumatic patient.

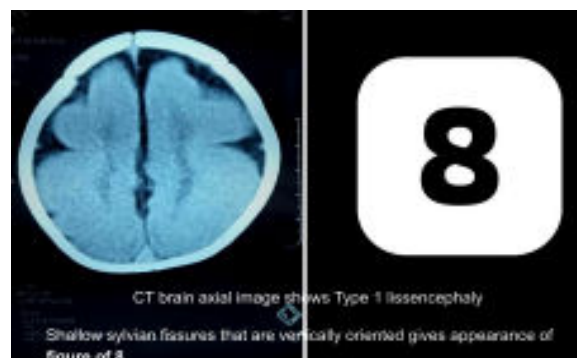

Prof Dr M A Taher

HOD, Department of Radiology & Imaging
BIRDEM General Hospital, Dhaka

Neurofibromatosis Type 1

Bilateral optic nerve glioma with proptosis and cerebral neurofibromas - Sequelae of Neurofibromatosis Type 1.

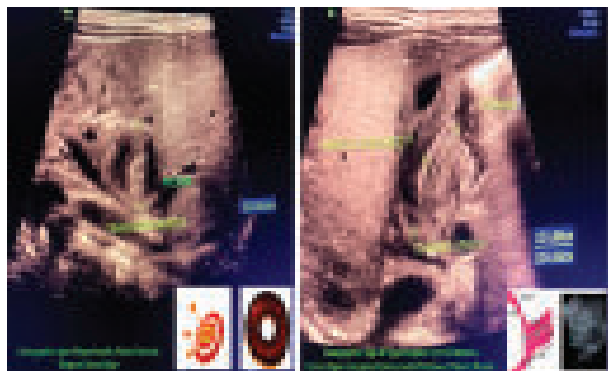


Dr Sajida Nahid

Assistant Professor, Department of Radiology & Imaging, Dhaka Medical College & Hospital, Dhaka

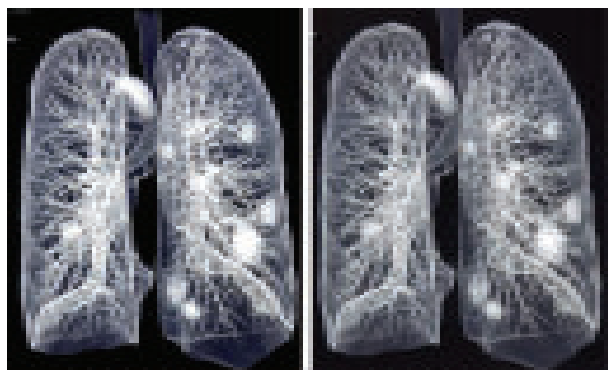
Figure of 8 Type 1 Lissencephaly

Vertically oriented shallow Sylvian fissures.



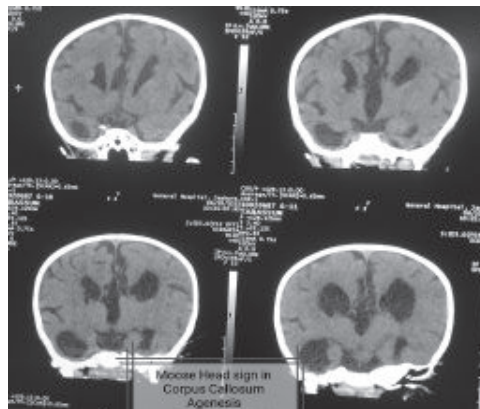
Dr Mahfuza Mahmud Chaiti
Assistant Professor, Department of Radiology & Imaging, Dhaka Medical College, Dhaka

Doughnut Sign & Cervix Sign in HPS.



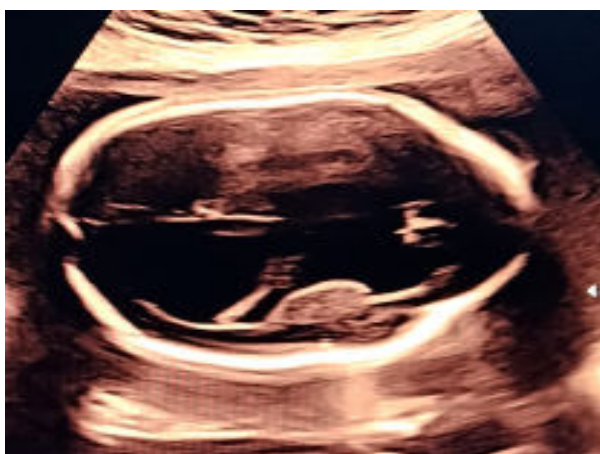
Dr Md Ubaidul Islam Bappy
Junior Consultant (Radiology & Imaging)
Cumilla

HRCT VRT Image for CT severity scoring.



Dr Farhana Hoque
Medical Officer
250 Beded General Hospital, Jashore

Moose Head Sign
In Corpus Callosum Agenesis.



Dr Nasima Akter
Associate Professor, Department of Radiology & Imaging, Universal Medical College, Mohakhali, Dhaka

Lemon Sign
Due to ventriculomegaly of fetus.